

## GENERAL GYNECOLOGY

## Green tea catechins for treatment of external genital warts

Sara M. Meltzer, MD; Bradley J. Monk, MD; Krishnansu S. Tewari, MD

More than 1 million new cases of anogenital warts are diagnosed each year in the United States alone.<sup>1</sup> Known also as condyloma acuminata, these warts result from infection with the human papillomavirus (HPV). The spectrum of diseases attributed to HPV infection runs the gamut from disfiguring genital warts and potentially lethal neonatal laryngeal papillomatosis (caused by HPV subtypes 6 and 11) to dysplastic and frankly invasive carcinomas of the cervix, vagina, vulva, and anus (caused primarily by oncogenic HPVs 16 and 18). Historically, treatment of anogenital warts has required chemical destruction, immunologic therapy, and/or surgical procedures, with many patients being treated with multiple therapeutic modalities, often leading to excessive scarring and disfigurement and ultimately, recrudescence of the disease. Recently, the US Food and Drug Association (FDA) granted approval to the green tea sinecatechin, Polyphenon E (Veregen) ointment for use in the treatment of anogenital warts in men and women. This review will highlight the biologic properties of catechins, report on clinical trials of Polyphenon E ointment in the management of anogenital warts, and illustrate the efficacy of this botanic with case presentations.

### Discovery of the medicinal properties of teas

Archeologic evidence suggests that tea plant culture is likely to have originated in China more than 5000 years ago, from where it was brought to India, Japan,

This review evaluates the antiviral, antioxidant, and immunostimulatory properties of green tea catechins. Two randomized trials evaluating the activity and efficacy of green tea catechins in the management of external genital warts are presented, and the reported side effects associated with this topical treatment modality are outlined. Finally, the mechanism of action, percent of wart clearance, time to clearance, and toxicity profile of green tea catechins are compared with those of podofilox and imiquimod, 2 other patient-administered topical agents approved for treatment of anogenital warts.

**Key words:** catechins, condyloma, external genital warts, green tea

Cite this article as: Meltzer SM, Monk BJ, Tewari KS. Green tea catechins for treatment of external genital warts. *Am J Obstet Gynecol* 2009;200:233.e1-233.e7.

Thailand, Korea, and Sri Lanka.<sup>2</sup> The medicinal properties of tea leaves first appeared in a Chinese book on pharmaceutical plants (ca 200 BC). Later, in the *Kissa Yojoki (Book of Tea, ca 1191)*, tea was listed as a remedy to control bleeding, help wounds heal, regulate body temperature, control blood sugar, and promote digestion.<sup>2,3</sup>

Green tea, which constitutes 20% of the tea manufactured worldwide, is probably the most consumed beverage besides water in Asian society (Figure 1). The main substances found in green tea are caffeine (2-4%), amino acids (4%), lignin (6.5%), organic acids (1.5%), protein (15%), chlorophyll (0.5%), and the polyphenols (25-35%).<sup>4</sup> The beneficial effects of green tea are attributed to the polyphenolic compounds present that are essentially colorless. Epigallocatechin gallate (EGCG) and epigallocatechin (EGC) are the most important polyphenols (Figure 2), and a cup of green tea contains about 300-400 mg of polyphenols or 10-30 mg of EGCG.<sup>4</sup> Because of the differences in the processing of tea leaves after harvest, catechins are present in higher quantities in green tea than in black or oolong tea.

Polyphenon E (Veregen) ointment is a botanical drug consisting of more than 85% catechins that has been approved by the FDA for the topical treatment of anogenital warts (Veregen ointment, 15% [NDA 21-902, Oct. 31, 2006]). These catechins are a partially purified fraction

of water extract of green tea leaves from *Camellia sinensis (L.) O Kuntze*.<sup>5</sup> Polyphenon E (Veregen) ointment represents the first, and at present, only FDA approved botanic for treatment of human disease. Its established efficacy in eradicating anogenital warts results from antiviral, immunostimulatory, and antioxidant mechanisms.

### Biologic properties of green tea catechins

The spectrum of biologic activities of green tea catechins appears in Table 1. In addition to possessing antiviral<sup>6-8</sup> and immunostimulatory<sup>9-12</sup> properties, catechins also exhibit antitumor<sup>13-16</sup> and antioxidative<sup>11,17</sup> effects. There is also sufficient evidence for antiangiogenic activity.

### Antiviral properties

In its episomal form, the early gene E2 of the HPV prevents transcription of the viral oncogenes E6 and E7, leading to a nonmalignant phenotype. Integration into the host genome, however, results in disruption of E2 and therefore loss of suppression of E6 and E7, resulting in disruption of p53 and pRB (retinoblastoma) signaling and oncogenesis.<sup>6</sup> The potential for integration and thus malignant transformation appears to vary among different HPV types, with HPV types 16 and 18 being most common in invasive lower genital tract cancers and HPV types 6 and 11 being associated

From the Department of Obstetrics and Gynecology, University of California, Irvine, Medical Center, Orange, CA.

Received Feb. 8, 2008; revised May 19, 2008; accepted July 28, 2008.

Reprints not available from the authors.

0002-9378/\$36.00

© 2009 Mosby, Inc. All rights reserved.

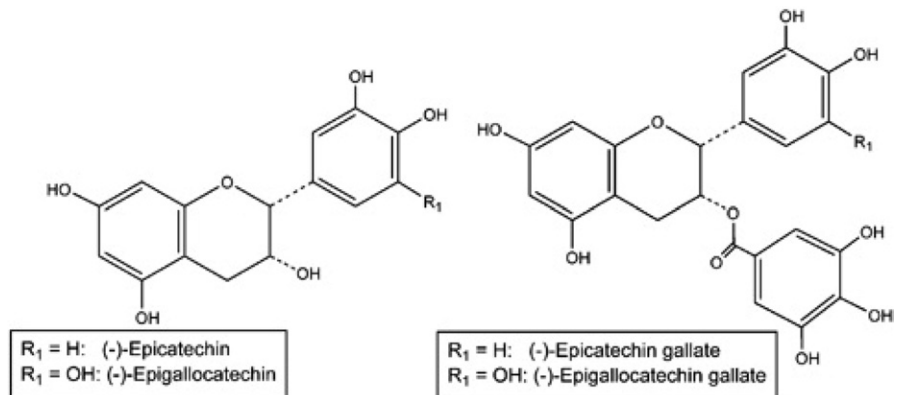
doi: 10.1016/j.ajog.2008.07.064

**FIGURE 1**  
**Green tea leaves**



Meltzer. Green tea catechins for treatment of external genital warts. *Am J Obstet Gynecol* 2009.

**FIGURE 2**  
**Chemical structure of catechins**



Meltzer. Green tea catechins for treatment of external genital warts. *Am J Obstet Gynecol* 2009.

**TABLE 1**  
**Biologic properties of green tea catechins**

Antiviral effects	Human papillomavirus	
	Adenovirus	
	Epstein-Barr virus	
	Influenza A and B	
	Rotavirus	
	Enterovirus	
	Human immunodeficiency virus <sup>a</sup>	
Anticarcinogenic properties	Modulation of signal transduction pathways through receptor tyrosine kinase activities	Epidermal growth factor receptor Platelet-derived growth factor receptor
	Induction of apoptosis	
	Cell cycle arrest	
	Reversal of multidrug resistance	
Antioxidative properties	Free radical scavenger	
	Inhibition of lipid peroxidation	
Antiangiogenic properties	Inhibition of microvessel formation	
	Inhibition of tyrosine phosphorylation of vascular epidermal growth factor receptor	
	Inhibition of extracellular matrix degradation by matrix metalloproteases	
Immunostimulatory effects	Interleukins	
	Tumor necrosis factors	
	Interferons	
Other biologic activities	Antimicrobial (mechanism unclear)	
	Antiatherogenic (inhibition of oxidation of low-density lipoproteins)	
	Anti-thrombotic (inhibition of collagen-induced platelet aggregation)	
	Promotion of thermogenesis	

<sup>a</sup> Possibly.

Meltzer. Green tea catechins for treatment of external genital warts. *Am J Obstet Gynecol* 2009.

with more than 90% of genital warts. As discussed later, catechins have demonstrated clinical efficacy in treatment of anogenital warts. This activity may be separate from their antiviral properties.

Hastak et al<sup>7</sup> demonstrated that the EGCG-induced apoptosis in human prostate carcinoma cells is mediated through stabilization of p53 by phosphorylation on critical serine residues. Khafif et al<sup>8</sup> studied the effects of EGCG in an oral leukoplakia cell line and noted growth inhibition through a G<sub>1</sub> block that was induced with an increase in the underphosphorylated form of pRB. Given the stabilization of the 2 key tumor suppressor gene products that are the targets of HPV-mediated transformation, it has been speculated that catechins thereby enhance cell cycle regulation and hinder HPV-induced cellular growth. There is no evidence available at this time that catechins have a direct interaction with the HPV oncogene products E6 and/or E7.

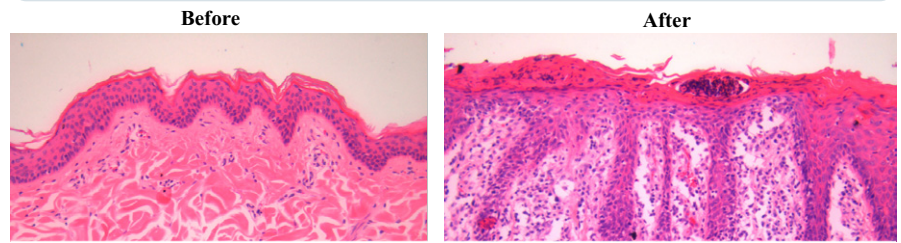
### Antiinflammatory and immunostimulatory properties

The antiinflammatory activity of the green tea catechins may, in large part, be accounted for by their antioxidant actions. EGCG has been found to inhibit the activity of the transcription factors AP-1 and NF-kappa B, both of which may mediate many inflammatory processes and both of which may be activated by reactive oxygen species.

Although Langerhans cells are often the first antigen-presenting cell that encounters infecting viruses in humans, these immune mediators are not activated by HPVs. However, catechins induce the release of many immune stimulatory interleukins while at the same time suppressing the release of immune inhibitory interleukins.<sup>9,10</sup> Specifically, catechins activate T lymphocytes, induce the release of both tumor necrosis factor-alpha (TNF- $\alpha$ ) and interferon-gamma (IFN- $\gamma$ ), and stimulate macrophages to release immune stimulatory cytokines. This promotes recruitment of monocytes, dendritic cells, lymphocytes, natural killer cells, and T-helper cells to aid in the immune response (Figure 3).

FIGURE 3

### Epithelial hyperplasia and neutrophil infiltration in murine tissue



Epithelial hyperplasia and neutrophil infiltration noted in murine tissue after topical application of Polyphenon E 15% ointment.

Meltzer. Green tea catechins for treatment of external genital warts. *Am J Obstet Gynecol* 2009.

Because the major neutrophil chemoattractant and inflammatory mediator, interleukin-8 (IL-8), is dependant on IL-1 $\beta$ , through inhibition of IL-1 $\beta$ , catechins decrease recruitment of neutrophils. Catechins also down-regulate CF8+ T cells and inhibit cyclooxygenase-2 (COX-2).<sup>11</sup> Down-regulation of the immune system via COX-2-mediated prostaglandin E2 (PGE-2) expression in epithelial cells has been linked to the development of dysplasia. Finally, at low doses, catechins stimulate mitogen-activated protein kinase (MAPK) pathways, thereby increasing transcription of protooncogenes c-jun and c-fos. At higher doses catechins activate c-jun N-terminal kinase (JNK) (an MAPK family member), leading to apoptosis.<sup>12</sup>

### Clinical trials of catechins for treatment of anogenital warts

It has been estimated that 75-80% of sexually active adults acquire a genital tract HPV infection before the age of 50

years.<sup>1</sup> The first age- and sex-specific estimates of the cost of anogenital warts was performed in 2000. Among privately insured patients for which an insurance claim was generated, each case of genital warts resulted in an average of more than 3 physician visits and \$436.<sup>18</sup>

Condylomas are often asymptomatic but may present with pruritus, pain, bleeding, burning, or vaginal discharge. They appear skin-colored and may be smooth papules or papilliform. Treatment consists of chemical destruction, immunologic therapy, or surgical excision; although 20-30% regress spontaneously. Chemical therapy aims to induce cell death. Podoflox arrests the tumor cell cycle, trichloroacetic acid (TCA) causes protein coagulation, and fluorouracil interferes with DNA synthesis. Immunologic therapy such as imiquimod induces cytokines. Surgery via cryotherapy, laser ablation, or excisional therapy is reserved for condylomas refractory to

TABLE 2

### Demographic profiles of the intent-to-treat populations in protocol 1017<sup>20</sup>

#### Intent-to-treat population in protocol 1017

Arms	Placebo	10% ointment	15% ointment	P value
No.	103	199	201	
Men	60.2%	55.3%	52.2%	.42
Women	39.8%	44.7%	47.8%	
Median age (range, y)	30.4 (18-60)	30.6 (16-98)	30.8 (17-69)	.91
White	94.2%	95.0%	95%	.93

Meltzer. Green tea catechins for treatment of external genital warts. *Am J Obstet Gynecol* 2009.



TABLE 3

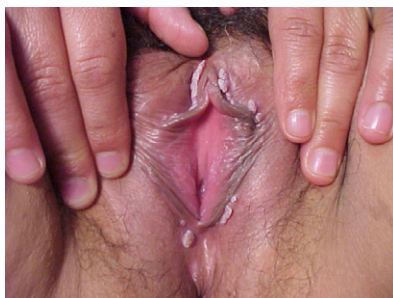**Complete clearance of all warts (baseline and new) during treatment in protocol 1017—female patients (intent-to-treat population)<sup>20</sup>****Protocol 1017—female patients**

Variable	Placebo	10% ointment	15% ointment
n	41	89	96
Complete clearance	41.5%	60.5%	58.1%
No complete clearance	58.5%	39.5%	41.9%
Odds ratio		2.159	1.955
95% CI		(1.013-4.603)	(0.928-4.119)
P value		.057	.092

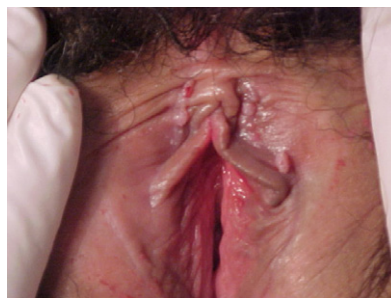
CI, confidence interval.

Meltzer. Green tea catechins for treatment of external genital warts. *Am J Obstet Gynecol* 2009.

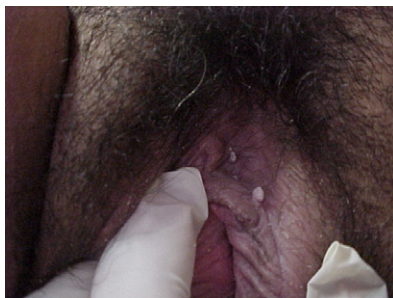FIGURE 4

**Results of topical therapy with Polyphenon E 15% ointment**

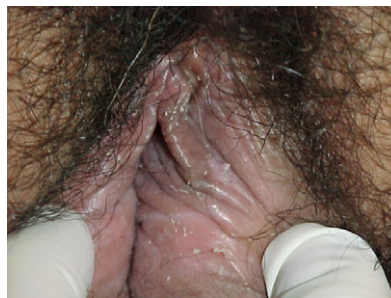Baseline



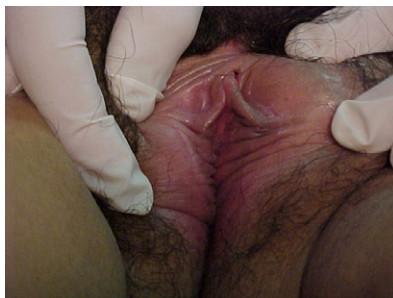Week 6



Week 8



Week 12



Week 16

Baseline appearance of vulvar warts and fully healed vulva after 16 weeks of treatment with green tea catechins.

Meltzer. Green tea catechins for treatment of external genital warts. *Am J Obstet Gynecol* 2009.

other treatment modalities. Although each of these treatment modalities is efficacious in some patients, they are not completely without side effects and sequelae. Chemical and immunologic therapy may cause pain and discomfort, while surgical intervention may result in infection, bleeding, and/or poor cosmetic outcome.

Three randomized, double-blind, placebo-controlled phase 3 trials were conducted to determine the efficacy and safety of the catechin, Polyphenon E given as a 10% and 15% ointment. These studies were powered to demonstrate the superiority of each of the 2 Polyphenon E ointment formulations over placebo with respect to the complete clearance rates of all baseline and new warts.

The first study (CT 1015) was reported by Gross et al<sup>19</sup> in 2007 and enrolled patients in 28 hospitals and clinical practices in Germany and Russia. One hundred twenty-five men and 117 women were randomly assigned to Polyphenon E 15% ointment, 10% ointment, or placebo. Treatment was administered for up to 12 weeks with a 12-week treatment-free follow-up. Randomized, double-blind, placebo-controlled study for up to 12 weeks with a 12-week treatment-free follow-up. For 15% ointment, statistically significant differences to placebo were achieved regarding complete clearance of all baseline external genital warts (61.0% vs 40.5% in men, 56.8% vs 34.1% in women; combined:  $P = .0066$ ). For 10% ointment, 53.8% men and 39.5% women achieved complete clearance. Recurrence rates 12 weeks after end of treatment ranged from 10.3% to 11.8% in the 3 arms.<sup>19</sup> Seven patients receiving 10% ointment, 9 patients receiving 15% ointment, and 3 receiving placebo experienced a total of 21 adverse events ( $n = 19, 7.9%$ ).<sup>19</sup> Only 6 of these patients (2.5%) experienced toxicities that were considered possibly or probably related to the study drug (hyperkeratosis and skin discoloration among 2 patients receiving 10% cream, and transient local necrosis, allergic dermatitis, or pain in the foreskin among 4 patients receiving 15% cream).<sup>19</sup>

AG Protocol CT 1017 was a randomized, double-blind, 3-arm parallel-group,

TABLE 4

## Patient-administered topical agents for treatment of external genital warts

Agent	Mechanism of action	Clearance	Time to clearance	Side effects <sup>a</sup>
Polyphenon E <sup>20,21</sup> (Veregen)	Antiviral Immunostimulatory Antioxidant Antitumor Antiangiogenic	58% (both sexes); 65% (women only)	Up to 16 wk	18% erythema 17% pruritis or burning 14% pain 12% ulceration 11% edema 9% induration 5% vesicular rash
5% Imiquimod (Aldara)	Immunostimulatory (cytokine induction)	37%	Up to 8 wk	32% itching 26% burning 8% pain 3% soreness 11% fungal infection < 5% headache, influenza-like symptoms, myalgia
Podofilox (Condylox)	Antimitotic activity leading to cell cycle arrest	20-50%	Up to 12 wk	78% burning 72% pain 67% erosion 63% inflammation 65% itching

<sup>a</sup> As contained in FDA package inserts.

Meltzer. Green tea catechins for treatment of external genital warts. *Am J Obstet Gynecol* 2009.

vehicle-controlled, multicenter Phase 3 trial that enrolled 226 women and 277 men from 46 dermatologic, gynecologic, and urologic centers throughout Europe and South Africa. The placebo-controlled trial studied the 15% and 10% Polyphenon E ointments, and the results were recently reported by Stockfleth et al.<sup>20</sup> The median age of the study population was approximately 30.7 years (range, 16-98 years), and in this study greater than 90% of subjects in each of the 3 arms were white (Table 2).<sup>20</sup> The median wart area was 51 mm<sup>2</sup> and the median wart number was 6. A clearance of greater than 50% was achieved in 77.3%, 78.0%, and 52.9% of all subjects in the Polyphenon E 15%, 10%, and placebo arms, respectively.<sup>20</sup> Women responded better than men, with approximately 60% of women (Table 3) and 45% of men in both active groups achieving complete clearance of all warts. The median times to complete clearance were estimated at 16.1 weeks for both the 15% and 10% ointments and 16.7 weeks for placebo ( $P < .001$ ). Adverse events other than mild local reactions that were probably related to study medication were reported by 4 pa-

tients (0.8%), including moderate balanitis, severe herpes simplex, mild lymphadenitis, and severe phimosis, all in the Polyphenon E 15% ointment group.

The third trial, AG Protocol CT 1018, randomly assigned 502 subjects (258 men and 244 women) to the 15% ointment, 10% ointment, and vehicle arms and was conducted in 50 health centers in the United States, Latin America, and Romania.<sup>21</sup> One hundred eleven subjects (57.2%) in the 15% ointment arm, 111 subjects (56.3%) in the 10% ointment arm, and 35 subjects (33.7%) in the vehicle arm achieved complete clearance of all external genital warts ( $P < .001$ ).<sup>21</sup> Compared with male patients, the proportion of female patients with complete clearance of all warts was higher in all 3 treatment groups. Recurrences occurred in 6.5% to 8.8% of patients in all 3 arms during the 12-week follow-up period. Severe adverse events, comprising lymphadenitis, skin ulcer, vulvitis, and vulvovaginitis, were reported for 5 patients treated with 15% ointment and for 2 treated with 10% ointment.<sup>21</sup>

In each of the 3 studies there were patients on the placebo arms who experienced complete clearance of warts. There

is the possibility that high placebo response is linked to the known potential of 2 excipients: oleyl alcohol and isopropylmyristate (IPM). Importantly, IPM has some known irritant potential, and it is thought that with 3 times daily application along with mechanical stimulus and change in hygiene, this may lead to higher spontaneous clearance. It is also interesting to note that in 2 of the studies (AG 1017 and 1018), the complete clearance rates for sinocatechins ointment was higher in women than in men, although the sex differences were relatively small. Lower clearance rates in men have been linked to greater keratinization of the skin along the penile shaft, affecting drug penetration.<sup>22</sup> A case study demonstrating progressive resolution and clearance of vulvar condyloma after topical therapy with Polyphenon E 15% ointment appear in Figure 4.

Table 4 lists the properties, activity, and side effects associated with green tea catechins and the 2 other patient-administered topical agents approved by the FDA for treatment of anogenital warts: podofilox and imiquimod. Podophyllo-toxin (podofilox) is a nonalkaloid toxin in the lignan family and was the first

FDA-approved gel for the treatment of genital warts. Tyring et al<sup>23</sup> reported the outcomes of 326 patients with anogenital warts who were randomly assigned in a double-blind, vehicle-controlled, multicenter trial. In the intent-to-treat analysis, after 8 weeks of therapy 62 of 167 patients (37.1%) treated with 0.5% podofilox gel had complete clearance of the treated areas compared with 2 of 86 patients (2.3%) who had clearing of warts with the vehicle gel ( $P < .001$ ).<sup>23</sup> The 0.5% podofilox gel was well tolerated, with only 7 patients (3.2%) discontinuing study treatment because of drug-related local reactions.<sup>23</sup> The marketed trade name product Condylax is a 0.5% podofilox gel.

Imiquimod is capable of inducing a variety of cytokines, including INF- $\alpha$ , TNF- $\alpha$ , as well as IL-1, -6, and -8. Beurner et al<sup>24</sup> conducted a prospective, double-blind, placebo-controlled trial in 108 subjects, 51 of whom were randomly assigned to the imiquimod 5% arm and 57 to the placebo. Complete clearance of warts was reported for 37% of the imiquimod-treated patients, and in 0% of the placebo group ( $P < .001$ ). Three (19%) of the 16 patients who experienced complete clearance of warts had a recurrence develop during the 10-week follow-up period.<sup>24</sup> Subjects in the imiquimod arm experienced a significantly greater number of local inflammatory reactions, which ranged from pain and ulceration (8.3-10.4%) to itching (54.2%). Imiquimod 5% received FDA approval in 1997 and is marketed by MEDA AB, Graceway Pharmaceuticals, and iNova Pharmaceuticals under the trade name Aldara. Although the clearance rates listed in Table 4 suggest that Polyphenon E preparations have higher rates when compared with podofilox and imiquimod, it should be recognized that from the available clinical trials time to clearance can be up to 16 weeks for Polyphenon E as compared with up to 8 weeks (imiquimod) and 12 weeks (podofilox).

### Summary

Although FDA approval of Gardasil quadrivalent HPV 6/11/16/18 recombinant virus-like particle vaccine (Merck &

Company, Inc, Whitehouse, NJ) may make significant inroads in eradicating HPV-related diseases, including invasive cervical cancer, lower genital tract dysplasias, and condyloma, it is anticipated that these benefits will not be realized for at least 1 full generation, provided of course that mass vaccination campaigns are successful globally. Until that time comes, anogenital warts will continue to cause significant morbidity to millions of Americans. Until recently, most existing treatments have been only moderately effective. Randomized trials have demonstrated the efficacy of green tea catechins as topical therapy for anogenital warts with negligible toxicity. Not only is Polyphenon E (Veregen) ointment the first botanical approved for the treatment of anogenital warts, it represents the first botanical approved by the FDA under its current regulatory policy. Polyphenon E (Veregen) ointment received FDA approval on Oct. 31, 2006, and is patent protected until 2017. The price of Veregen for drug wholesalers is \$208.98 per 15-g tube. The addition of green tea catechins to the armamentarium provides patients with a new topical agent that can be used as first-line treatment or before embarking on surgical therapy should recrudescence of anogenital warts occur after other topical treatment(s). ■

### REFERENCES

1. Monk BJ, Tewari KS. The spectrum and clinical sequelae of human papillomavirus infection. *Gynecol Oncol* 2007;107:S6-15.
2. Demeule M, Michaud-Levesque J, Annabi B, et al. Green tea catechins as novel antitumor and antiangiogenic compounds. *Curr Med Chem Anticancer Agents* 2002;2:441-63.
3. Cooper R, Morre DJ, Moore DM. Medicinal benefits of green tea: part 1, review of noncancer health benefits. *J Alternative Complim Med* 2005;11:521-8.
4. Nagle DG, Ferreira D, Zhou YD. Epigallocatechin-3-gallate (EGCG): chemical and biomedical perspectives. *Phytochemistry* 2006;67:1849-55.
5. Cabrera C, Artacho R, Gimenez R. Beneficial effects of green tea—a review. *J Am Col Nutrition* 2006;25:79-99.
6. Tewari KS, Taylor JA, Liao SY, et al. Development and assessment of a general theory of cervical carcinogenesis utilizing a severe combined immunodeficiency murine-human xenograft model. *Gynecol Oncol* 2000;77:137-48.
7. Hastek K, Gupta S, Ahmad N, Agarwal MK, Agarwal ML, Mukhtar H. Role of p53 and NF- $\kappa$ B in epigallocatechin-3-gallate-induced apoptosis in LNCaP cells. *Oncogene* 2003;22:4851-9.
8. Khaffi A, Schantz SP, Al-Rawi M, Edelstein D, Sacks PG. Green tea regulates cell cycle progression in oral leukoplakia. *Head Neck* 1998;20:528-34.
9. Ahn WS, Huh SW, Bae S-M, et al. A major constituent of green tea, EGCG, inhibits the growth of a human cervical cancer cell line, CaSki cells, through apoptosis, G<sub>1</sub> arrest, and regulation of gene expression. *DNA Cell Biol* 2003;22:217-24.
10. Ahn W-S, Yoo J, Huh S-W, et al. Protective effects of green tea extracts (polyphenon E and EGCG) on human cervical lesions. *Eur J Cancer Prev* 2003;12:383-90.
11. Sutherland BA, Rahman RM, Appleton I. Mechanisms of action of green tea catechins, with a focus on ischemia-induced neurodegeneration. *J Nutr Biochem* 2006;17:291-306.
12. Rahman I, Biswas SK, Kirkham PA. Regulation of inflammation and redox signaling by dietary polyphenols. *Biochem Pharmacol* 2006;72:1439-52.
13. Zaveri NT. Green tea and its polyphenolic catechins: medicinal uses in cancer and non-cancer applications. *Life Sci* 2006;78:2073-80.
14. Won S-M, Park Y-H, Kim H-J, Park K-M, Lee W-J. Catechins inhibit angiotensin II-induced vascular smooth muscle cell proliferation via mitogen-activated protein kinase pathway. *Exp Molec Med* 2006;38:525-34.
15. Shimizu M, Weinstein IB. Modulation of signal transduction by tea catechins and related phytochemicals. *Mutation Res* 2005;591:147-60.
16. Kao YH, Hiipakka RA, Liao S. Modulation of endocrine systems and food intake by green tea epigallocatechin gallate. *Endocrinology* 2000;141:980-7.
17. Higdon JV, Frei B. Tea catechins and polyphenols: health effects, metabolism, and antioxidant functions. *Crit Rev Food Sci Nutr* 2003;43:89-143.
18. Insinga RP, Dasbach EJ, Myers ER. The health and economic burden of genital warts in a set of private health plans in the United States. *Clin Infect Dis* 2003;36:1397-403.
19. Gross G, Meyer K-G, Pres H, Thielert C, Tawfik H, Mescheder A. A randomized, double-blind, four-arm parallel-group, placebo-controlled phase II/III study to investigate the clinical efficacy of two galenic formulations of Polyphenon E in the treatment of external genital warts. *J Eur Acad Dermatol Venereol* 2007;21:1404-12.
20. Stockfleth E, Beti H, Orasan R, et al. Topical Polyphenon E in the treatment of external genital and perianal warts: a randomized controlled trial. *Br J Dermatol* 2008;158:1329-38.
21. Tatti S, Swinehart JM, Thielert C, Tawfik H, Mescheder A, Beutner KR. Sincatechins,

a defined green tea extract, in the treatment of external anogenital warts: a randomized, controlled trial. *Obstet Gynecol* 2008;111:1371-9.

**22.** Gollnick H, Barasso R, Jappe U, et al. Safety and efficacy of imiquimod 5% cream in

the treatment of penile genital warts in uncircumcised men when applied three times weekly or once per day. *Int J STD AIDS* 2001;12:22-8.

**23.** Tyring S, Edwards L, Cherry LK, et al. Safety and efficacy of 0.5% podofilox gel in

the treatment of anogenital warts. *Arch Dermatol* 1998;134:33-8.

**24.** Beurner KR, Spruance SL, Hougham AJ, Fox TL, Owens ML, Douglas JM Jr. Treatment of genital warts with an immune-response modifier (imiquimod). *J Am Acad Dermatol* 1998;38:230-9.